


HILDHOOD

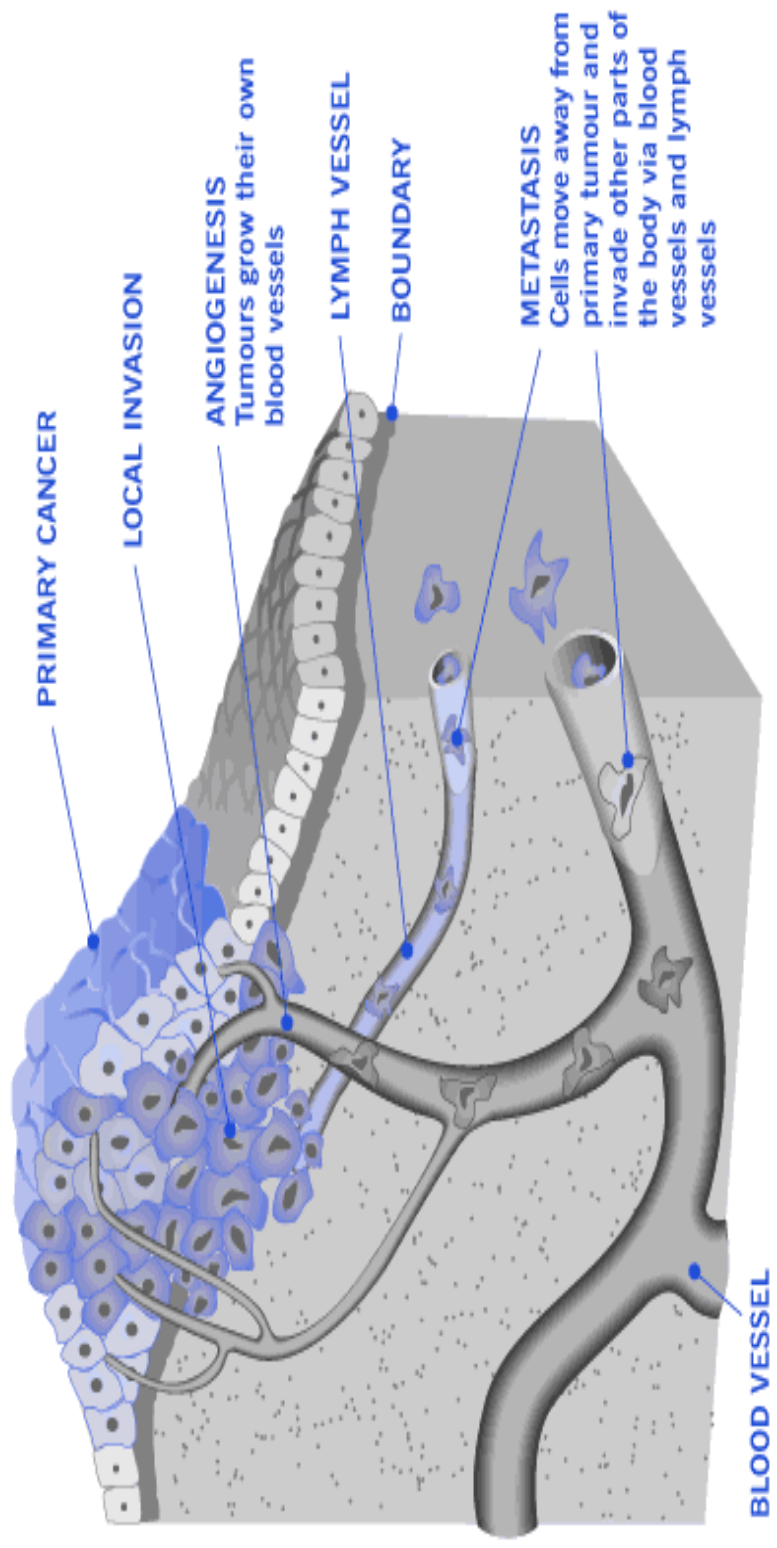
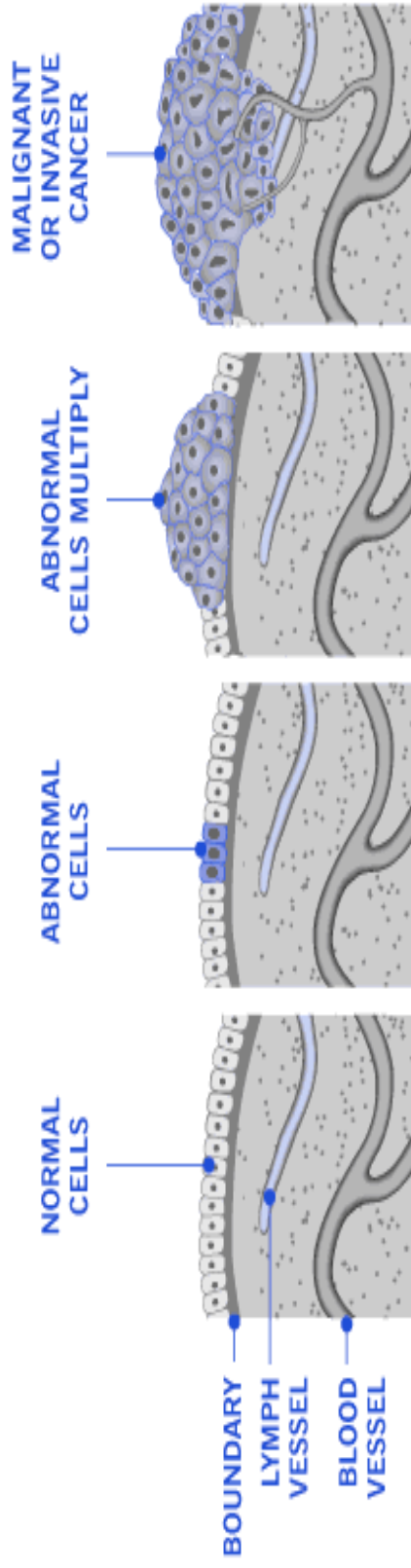
Cancer

dr. Edi Setiawan Tehuteru, Sp.A(K), MHA


Ini adalah...

Sel yang pertumbuhannya **tidak terkontrol**, sel yang **pandai**, dan sel **“preman”**



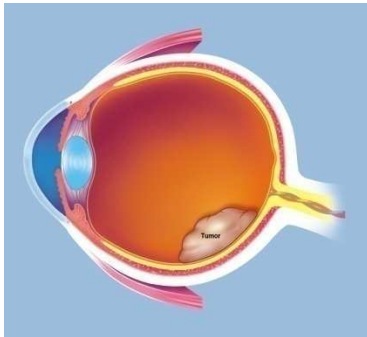
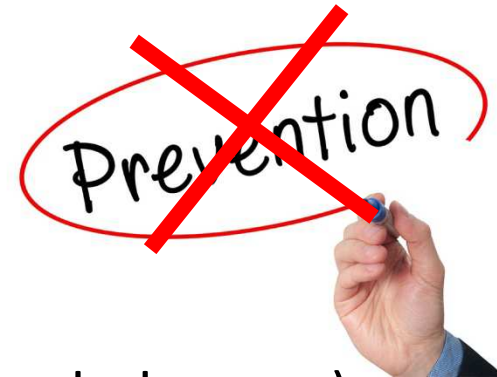

Fakta:



Penyebab kanker pada anak **tidak diketahui** secara pasti

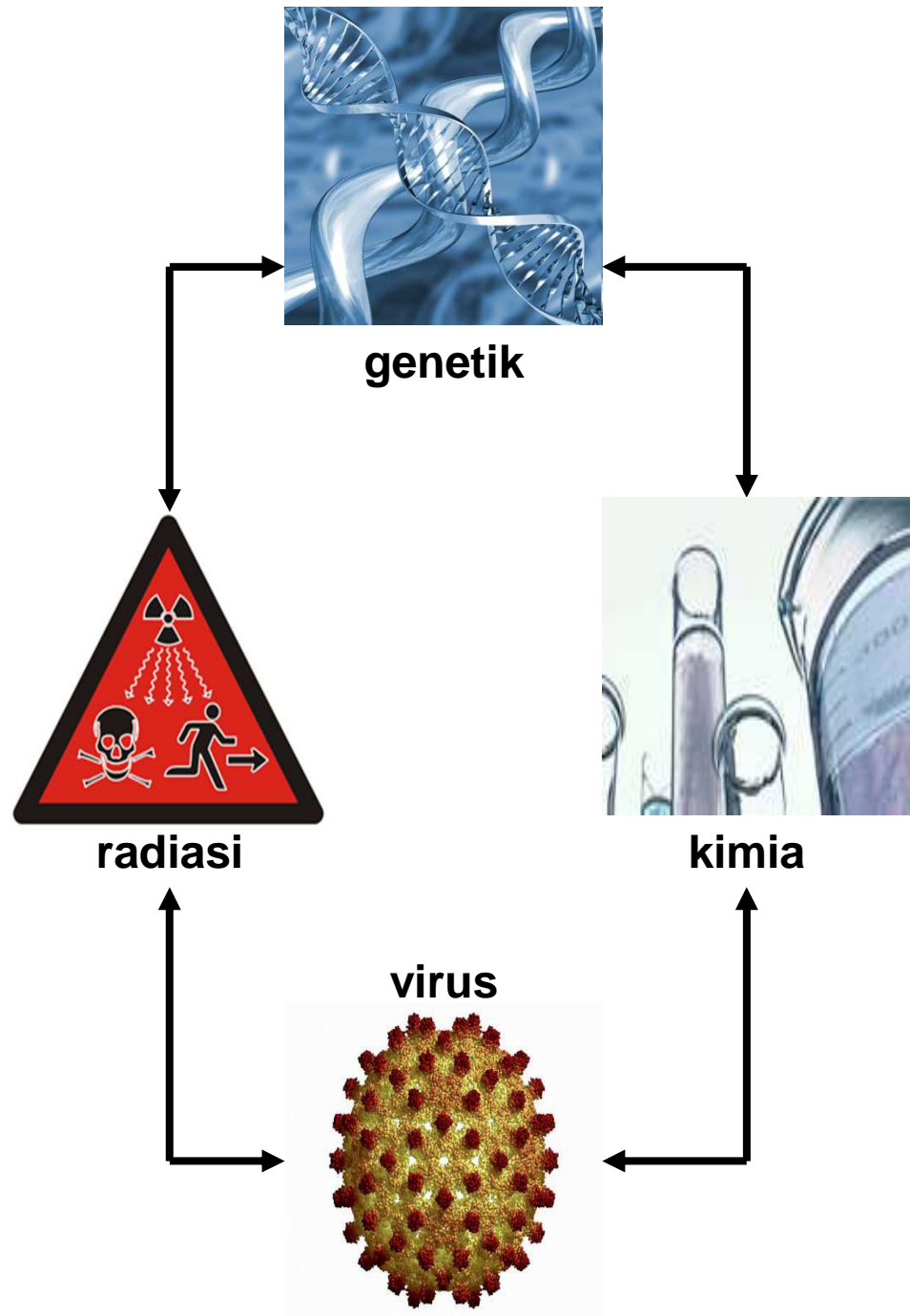
Kanker pada anak **tidak dapat dicegah**



Retinoblastoma (kanker bola mata) merupakan **satu** dari sekian jenis kanker pada anak yang dapat dideteksi dini

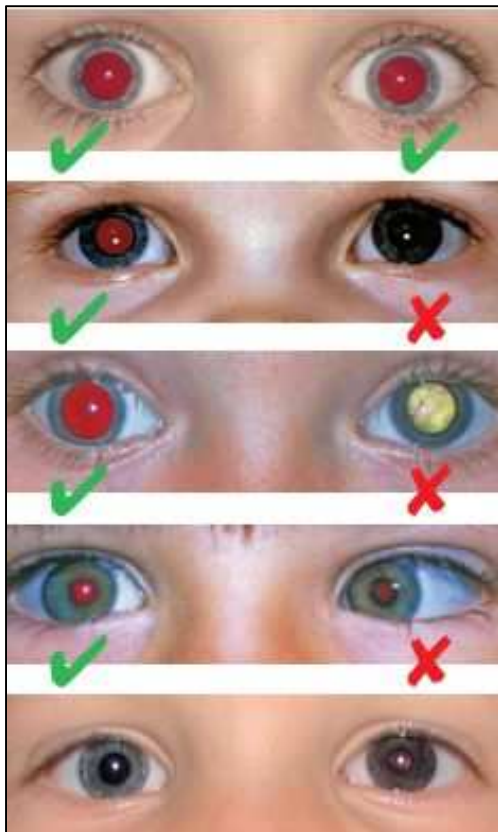


**Apa Penyebab
Kanker pada
Anak ?**



Retinoblastoma

Deteksi Dini: Lihat Merah



Childhood Eye Cancer Trust
Fighting Retinoblastoma



See Red

Red reflex examination of the eyes can be used to great advantage in young children.

The photographs shown here depict the inequality or absence of red reflex that can occur in several important eye conditions, the most serious of which is retinoblastoma. Red reflex examination is essential post-natally, at the 6 week check, routine development examinations, and at any consultation where a child is being examined due to parental concern over vision or eye appearance.

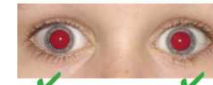Technique

Sit at arms length; use a good quality halogen light ophthalmoscope set close to zero focussed on the child's face; encourage the child to look at the lights. If it is unclear whether the reflex is normal or not then pupil dilation with drops such as tropicamide 1% will help. Examination of parents' eyes will help to recognise normal red reflexes in different ethnic groups. The corneal reflex can be checked at the same time.



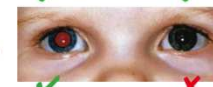Normal red reflex and corneal reflex

The colour and brightness of the red reflex, and the location of the small white corneal reflex, is identical in each eye.



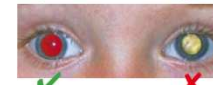Red reflex absent

An absent red reflex in one or both eyes demonstrates serious eye disease (such as cataract or retinoblastoma) requiring immediate referral.



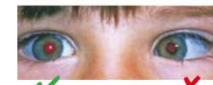Red reflex is abnormal

A red reflex that is the wrong colour or brightness in one or both eyes suggests serious eye disease (such as cataract or retinoblastoma) requiring immediate referral.



Combined with corneal reflex

The red reflex is reduced in the left eye and the corneal reflex is not central. This is a squint which requires prompt referral to exclude serious underlying disease.



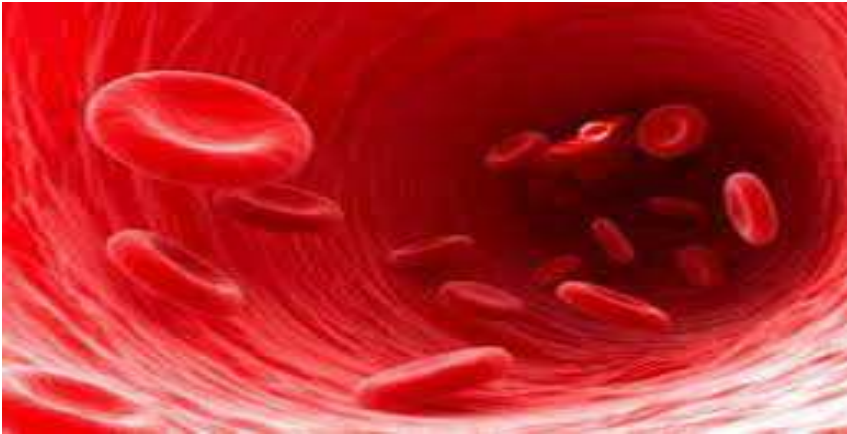This poster has been produced by the Childhood Eye Cancer Trust, with the help from Dr Al Smith and Birmingham Children's Hospital. The Childhood Eye Cancer Trust is a registered UK charitable organisation dedicated to support of families with retinoblastoma.

The Childhood Eye Cancer Trust can be contacted on:
Tel: 020 7377 5578 Email: info@cect.org.uk
See our website for more information: www.cect.org.uk

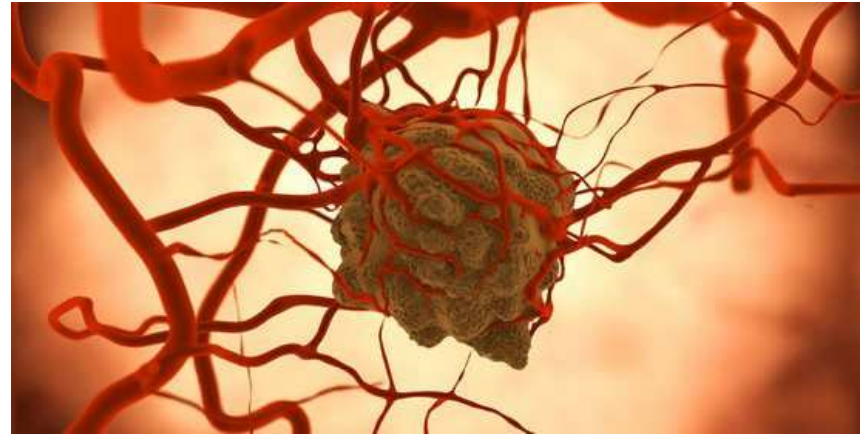
Oleh karena itu...



Kanker pada Anak

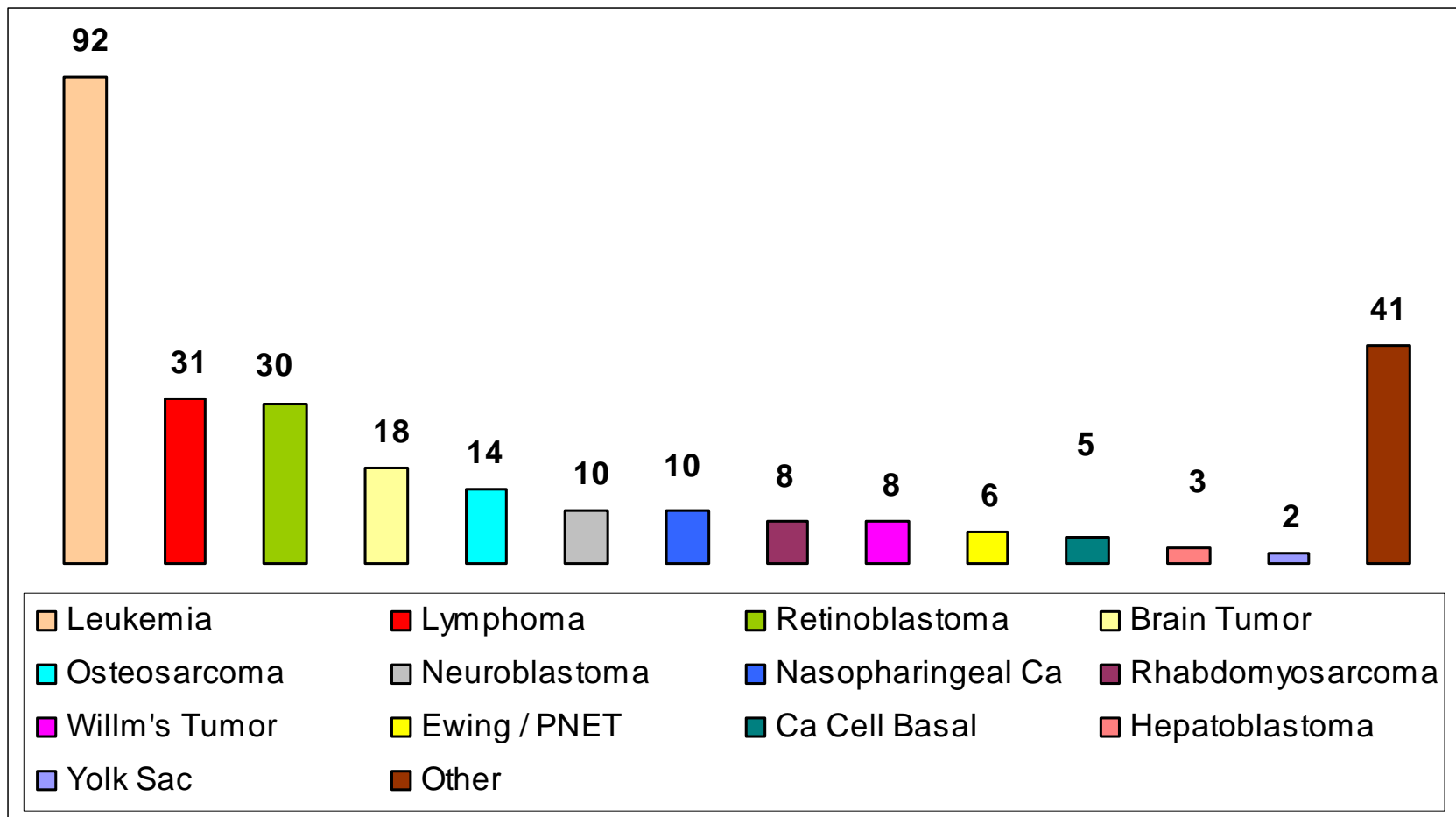


- Cair:
Leukemia



- Padat:
Kanker otak, bola mata,
nasofaring, otot polos,
kelenjar getah bening,
dan lain-lain

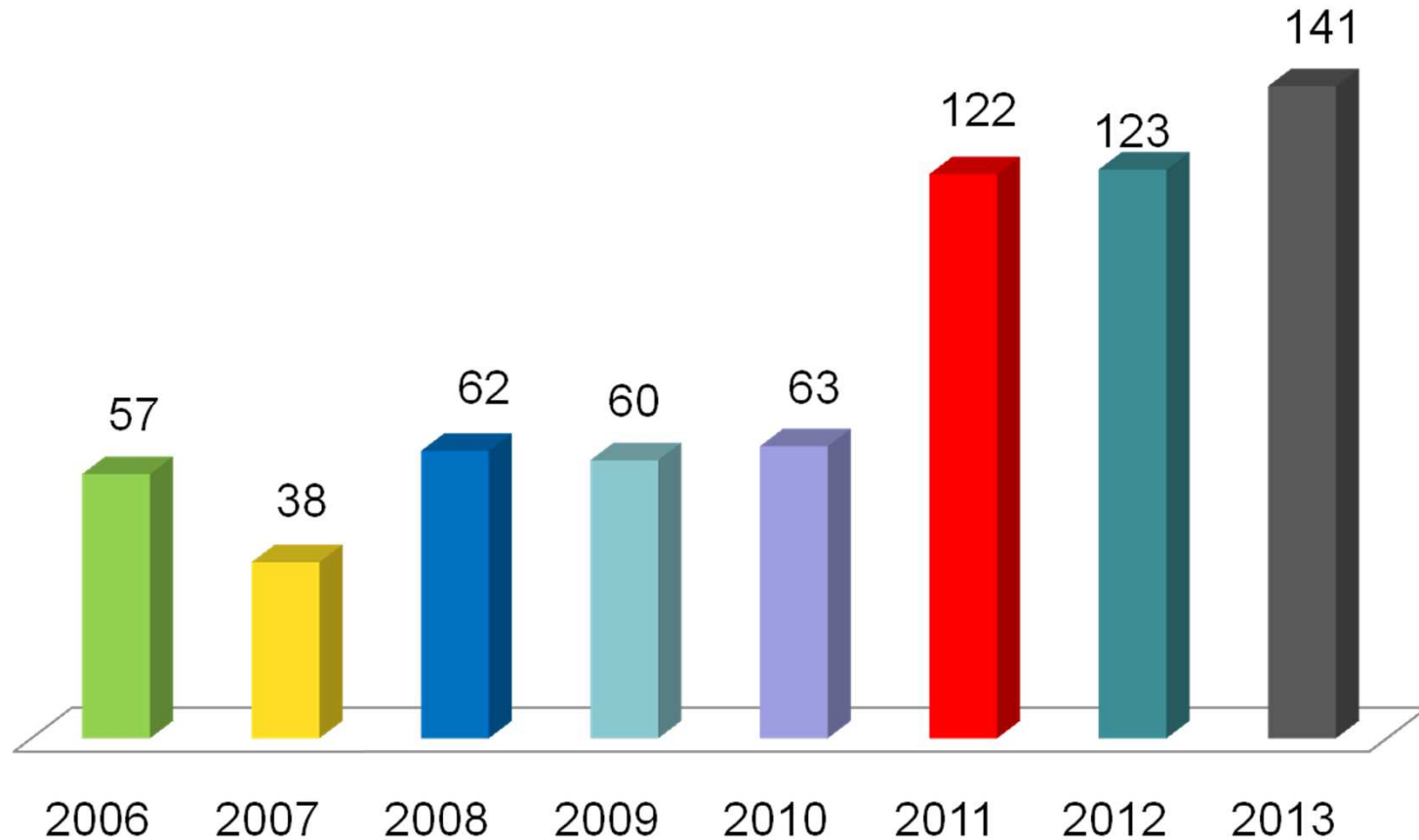
Distribution of Childhood Cancer in “Dharmais” Cancer Hospital 2006-2010



Source: Childhood Cancer Registry, Dept. of Child Health, DCH



Distribution of Childhood Cancer in “Dharmais” Cancer Hospital in 2006 – 2013

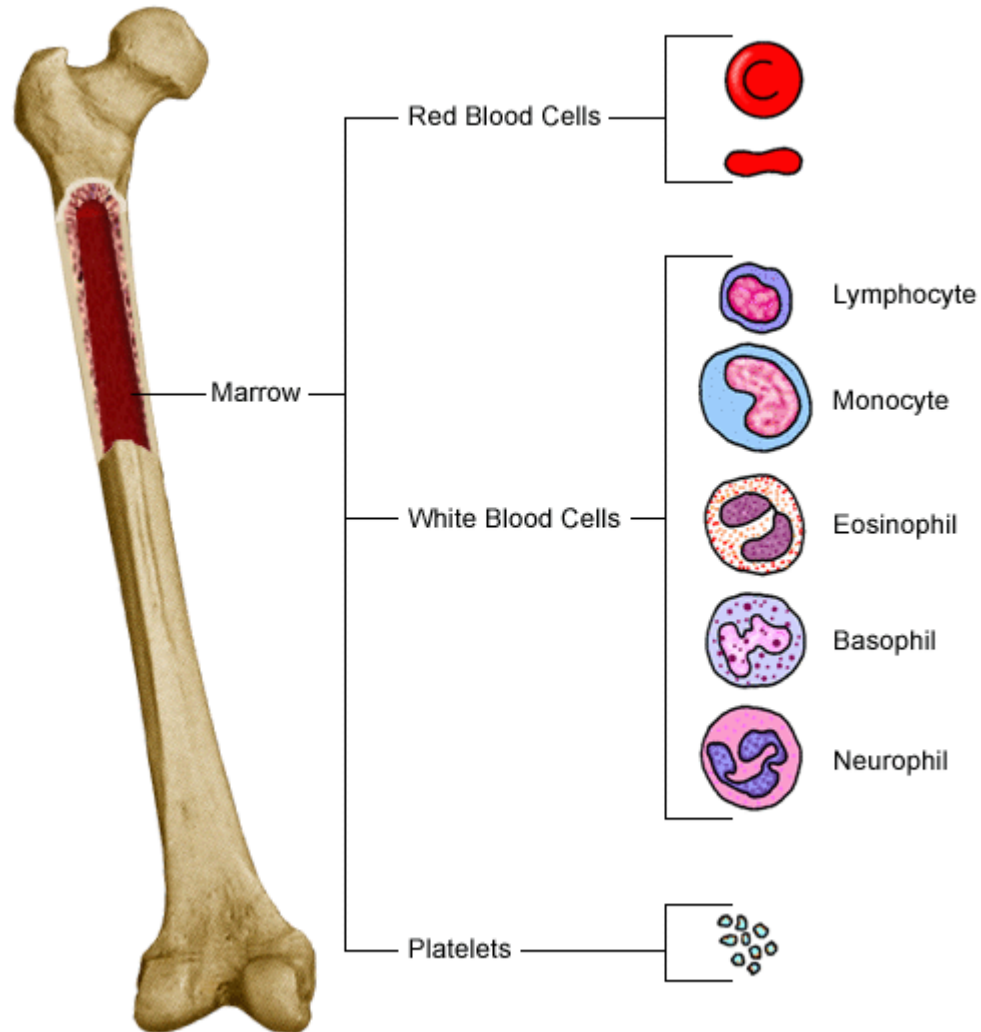


Source: Childhood Cancer Registry, Dept. of Child Health, DCH



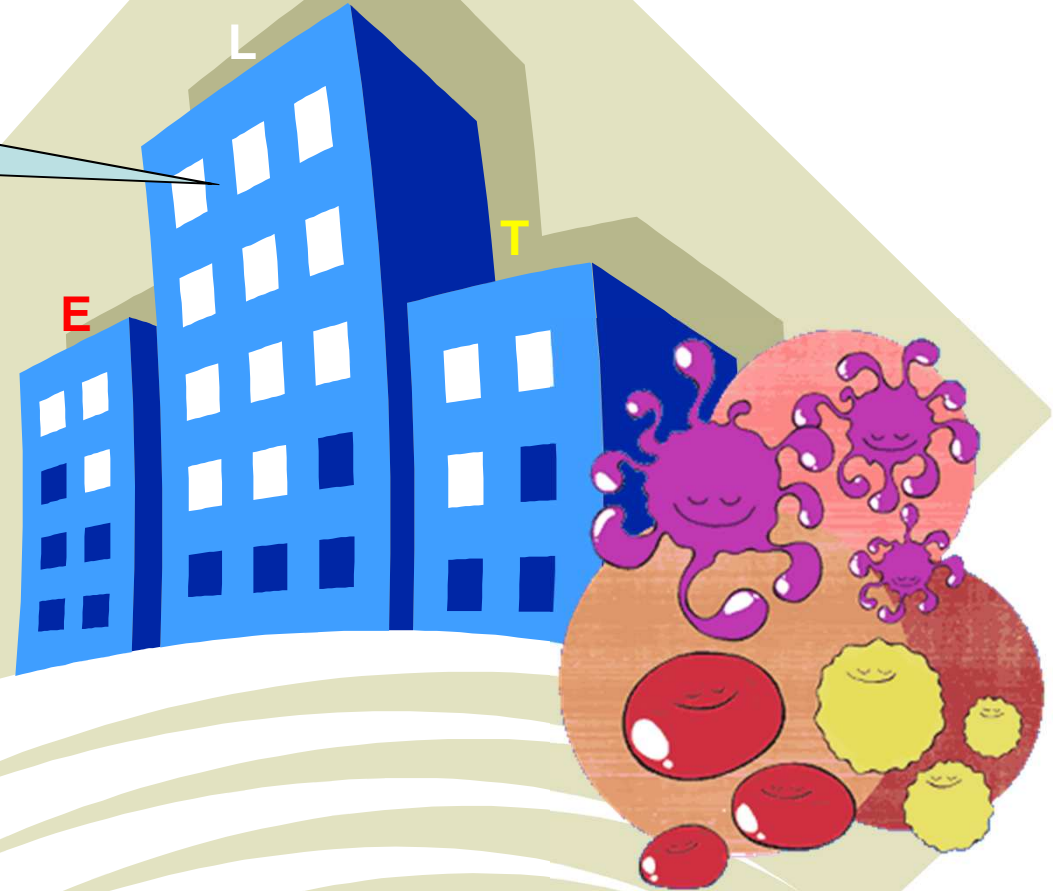
[LEUKEMIA]

Sel-sel darah diproduksi di...



SUMSUM TULANG IBARAT PABRIK

Buruh
DEMO

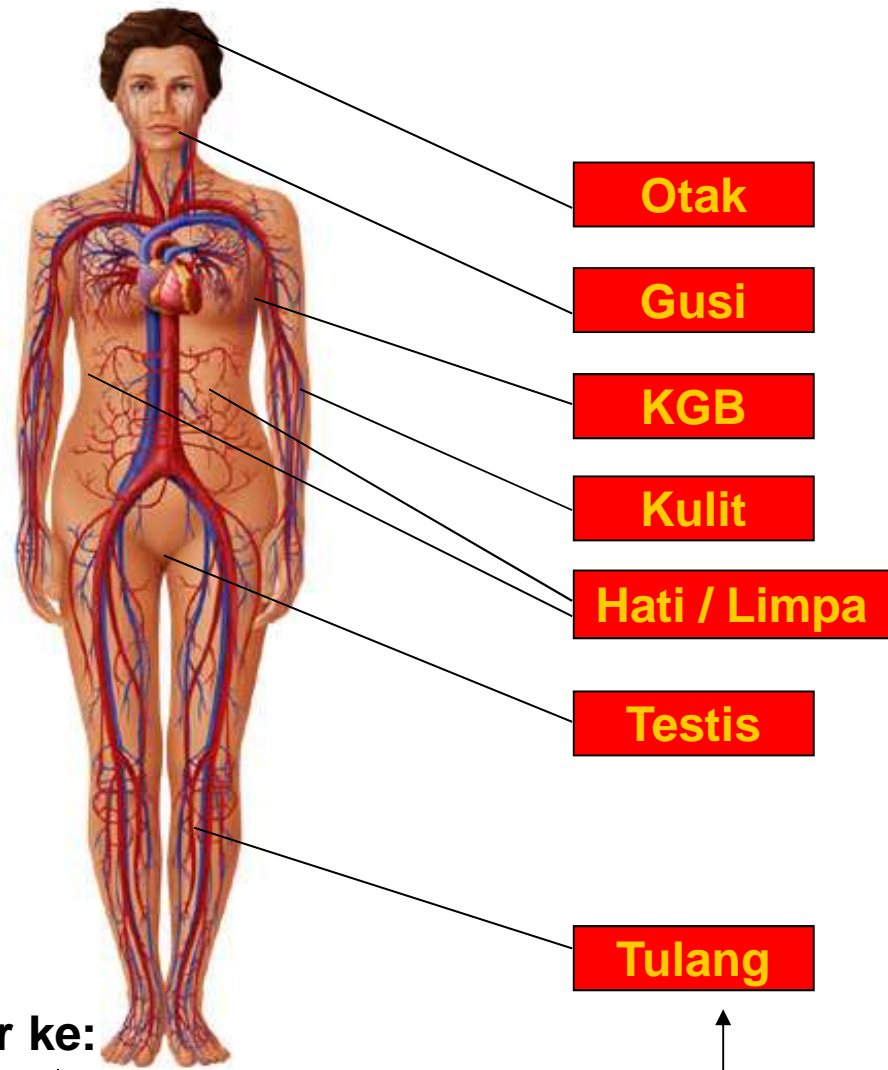


PRODUKSI KETIGA PABRIK MENURUN

TIDAK PUAS HANYA DI PABRIK...

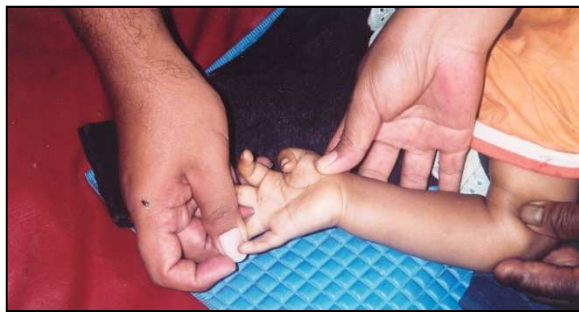GANAS

Menyebar ke:



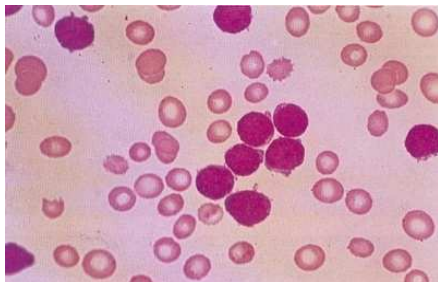
Apa yang harus diwaspadai ?

- Kegagalan Sumsum Tulang (Leukemia)



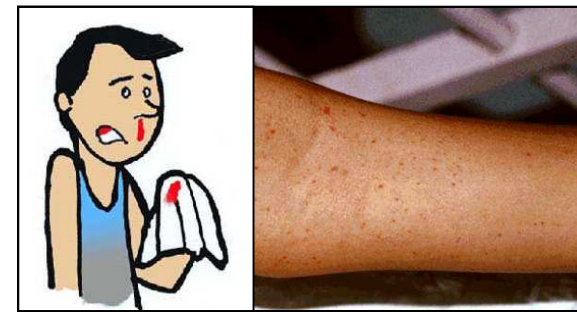
PUCAT / LESU

**SEL DARAH MERAH
RENDAH**



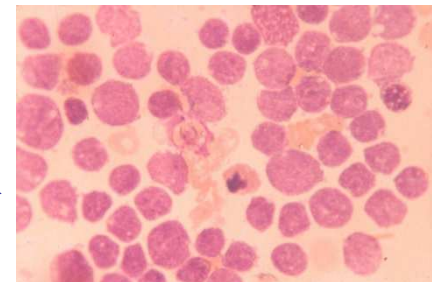
**DEMAM
(INFEKSI / SEPSIS)**

**SEL DARAH PUTIH
RENDAH**



PERDARAHAN

**KEPING DARAH
RENDAH**

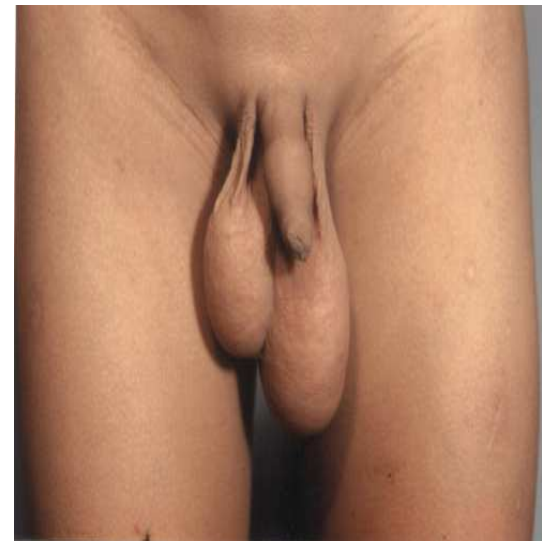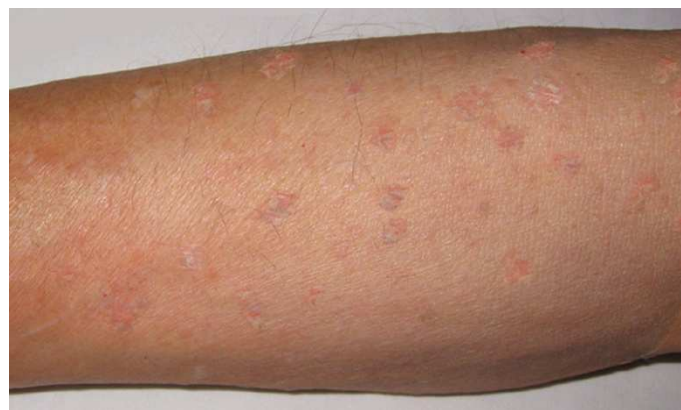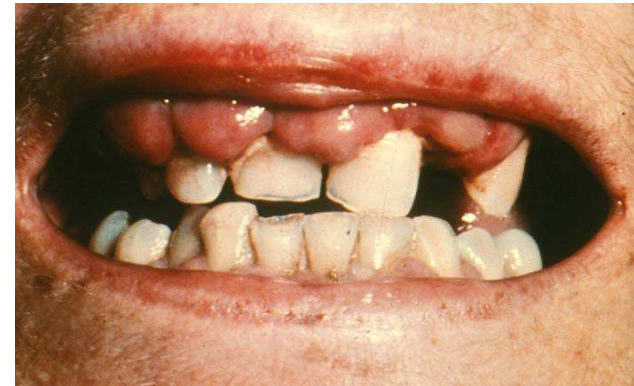


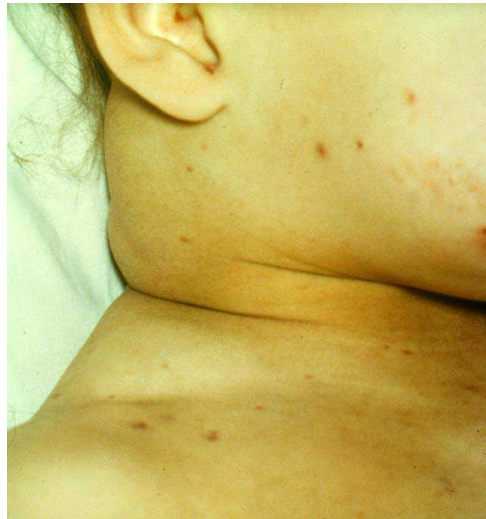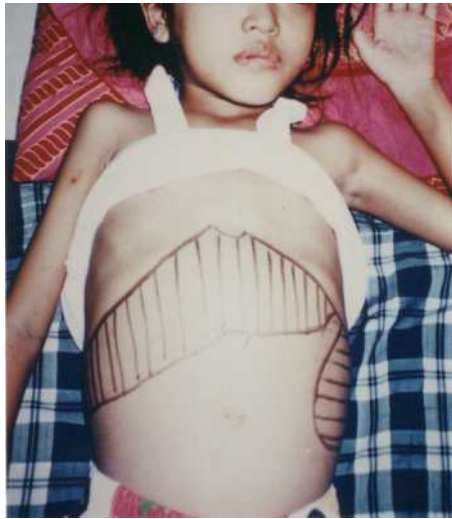**DARAH TEPI
SUMSUM TULANG**



Apa yang harus diwaspadai ?

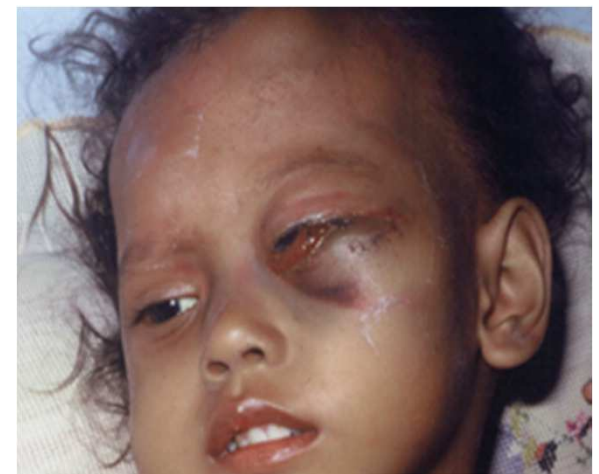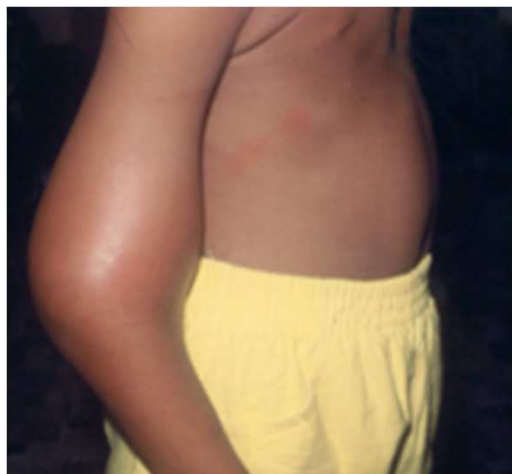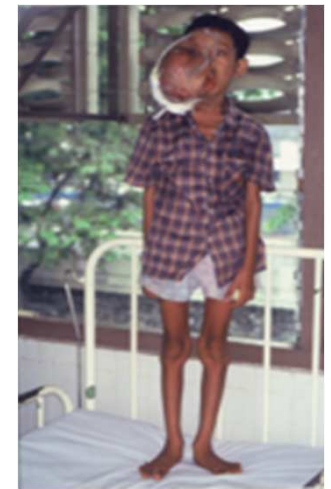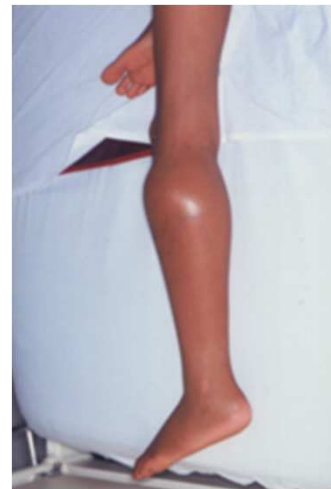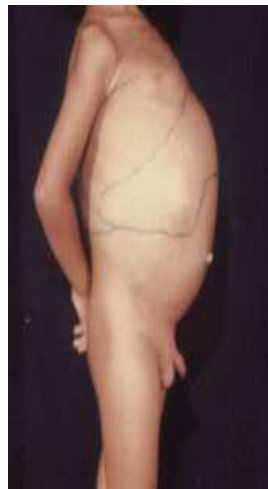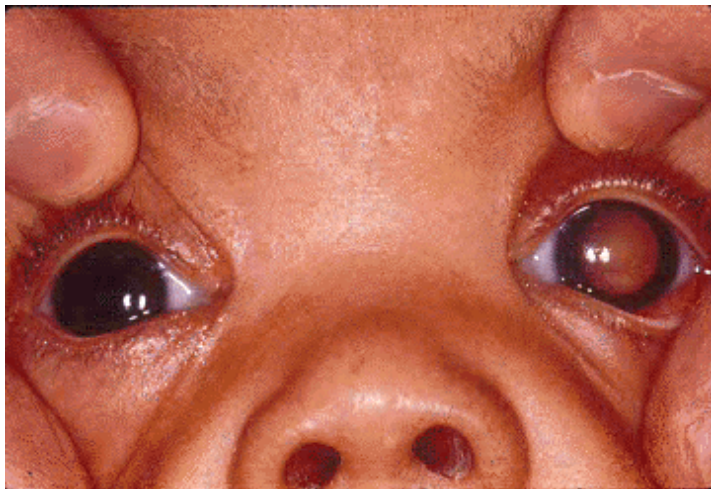- Penyebaran ke Jaringan / Organ (Leukemia)



[TUMOR PADAT]

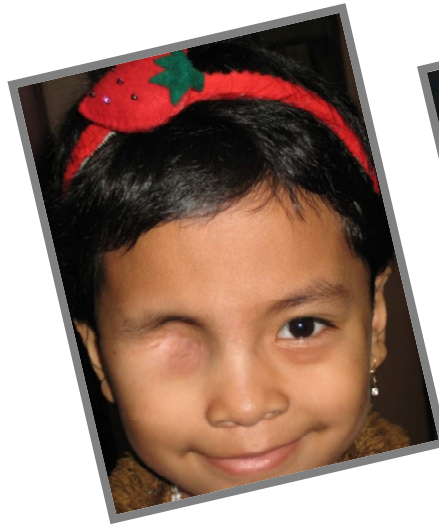
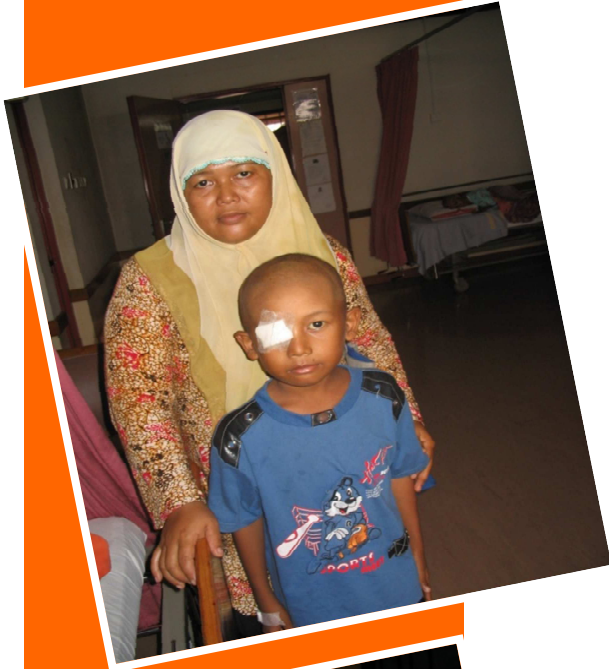
Apa yang harus diwaspadai ?



[DAMPAK?]

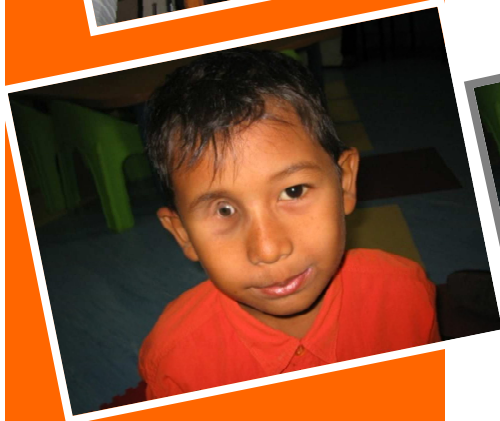Prognosis

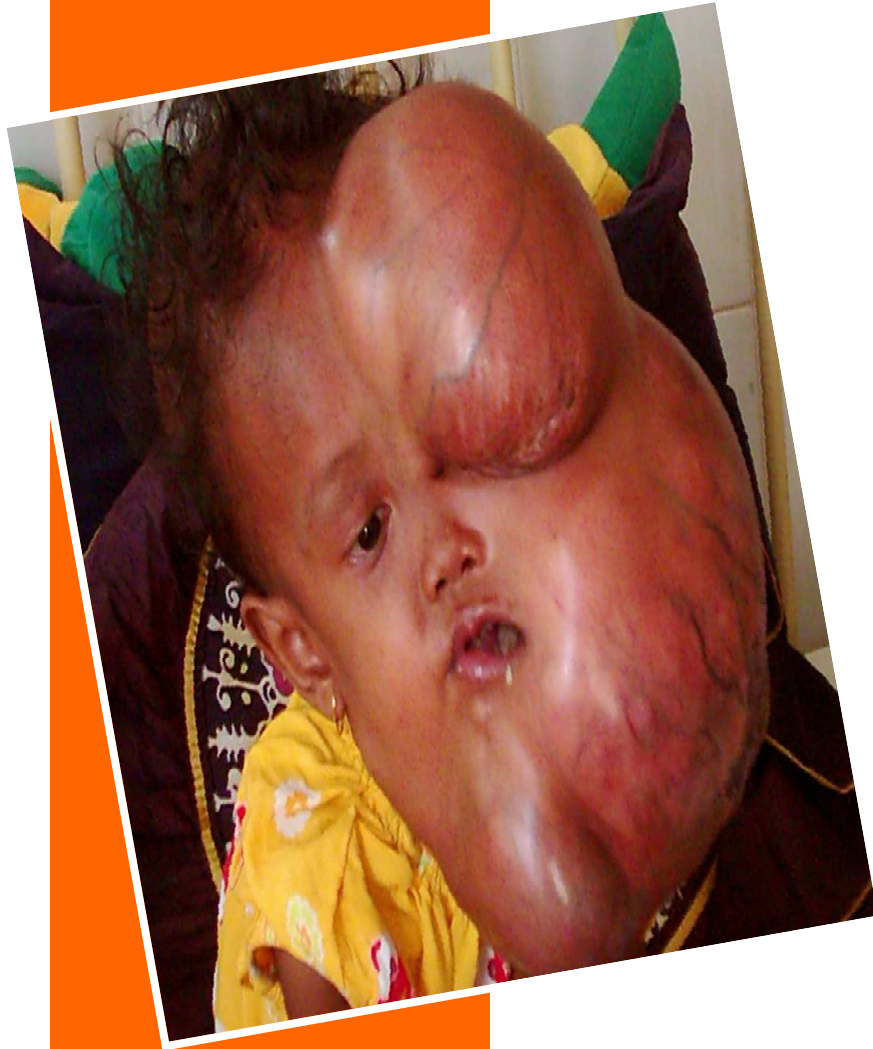

Retinoblastoma :

Angka harapan hidup bebas tumor 2 tahun

Stadium awal : 80%



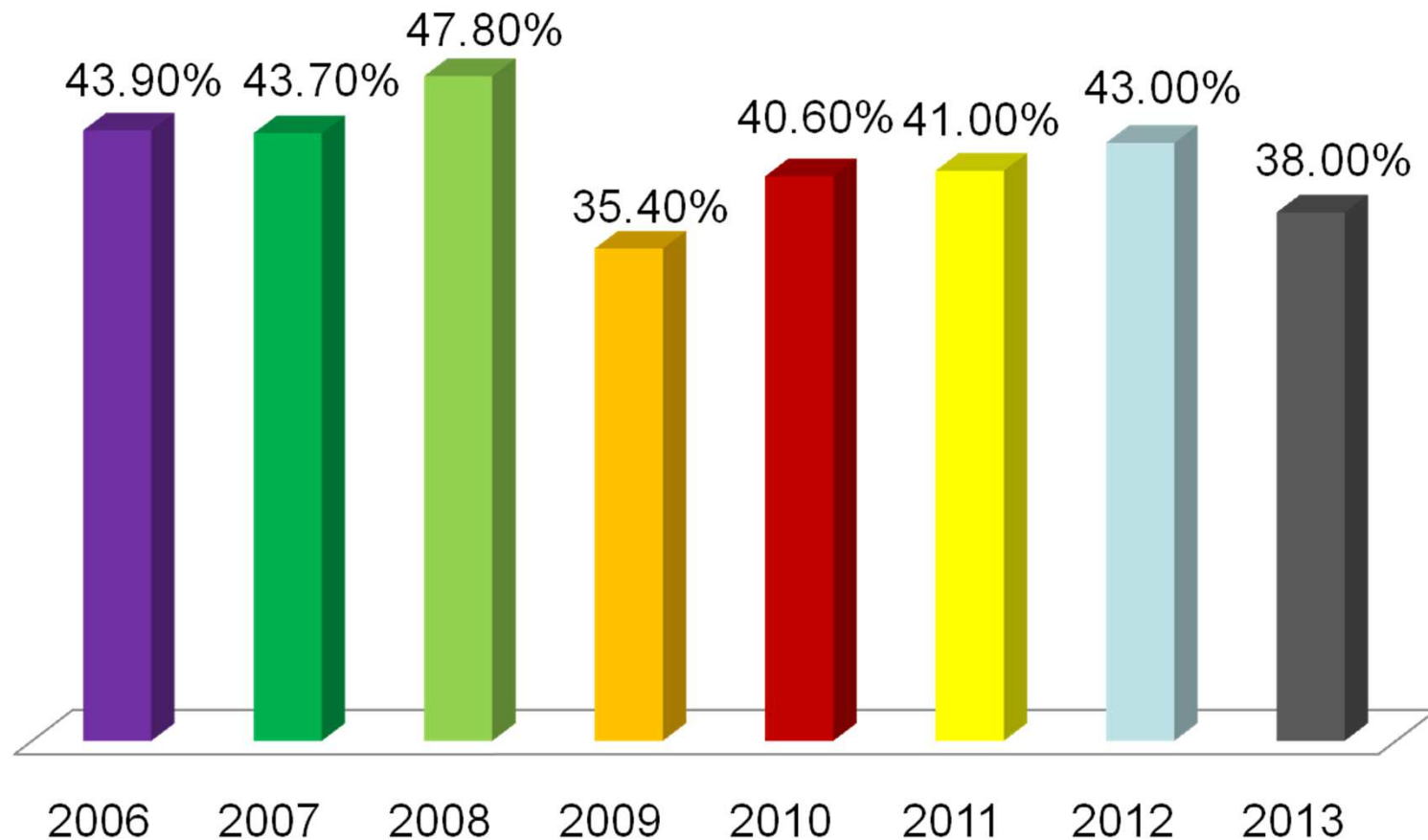


Retinoblastoma :

Angka harapan hidup bebas tumor 2 tahun

Stadium lanjut : 25%

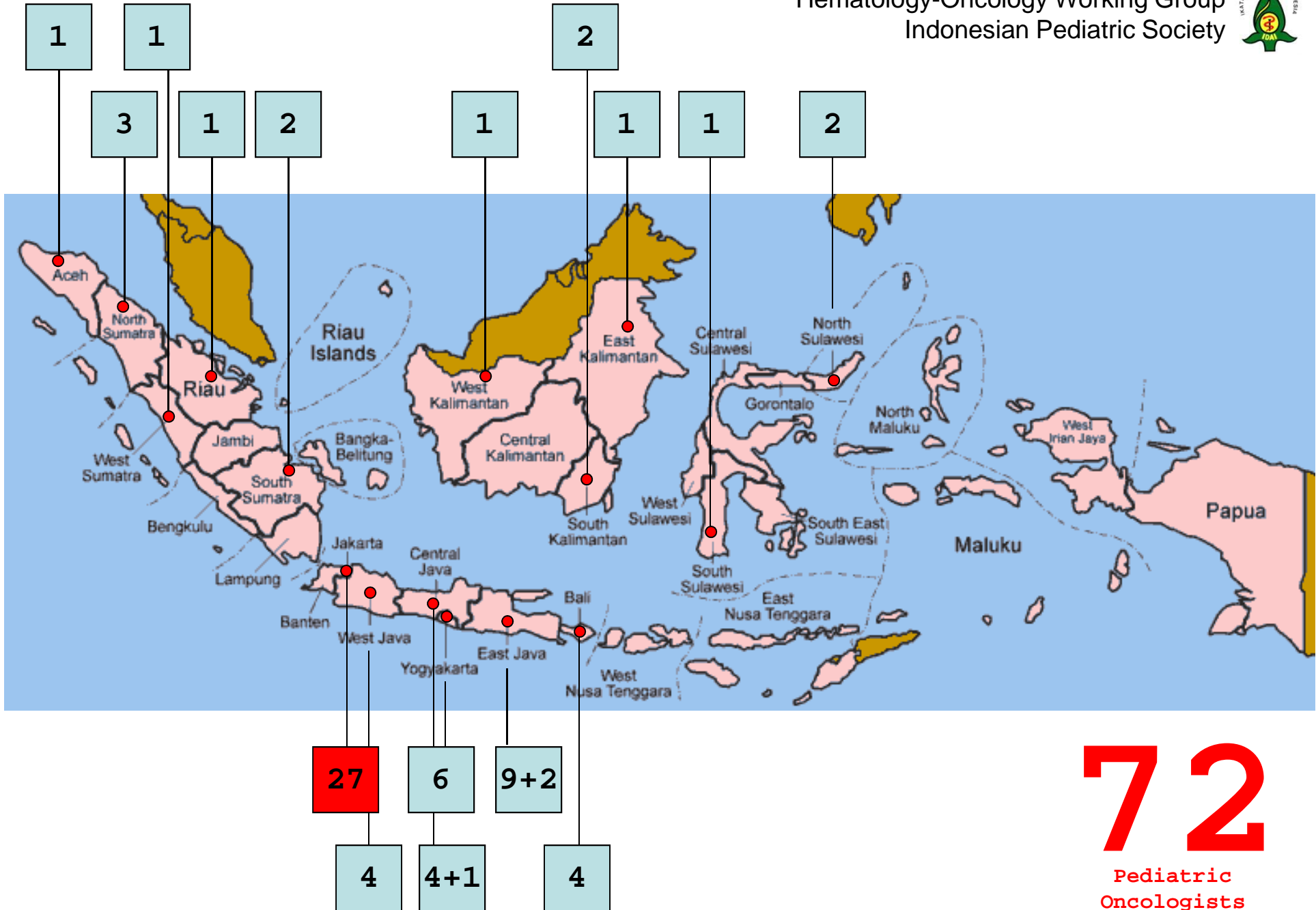Distribution of Childhood Cancer in “Dharmais” Cancer Hospital According to Last Stage 2006-2013



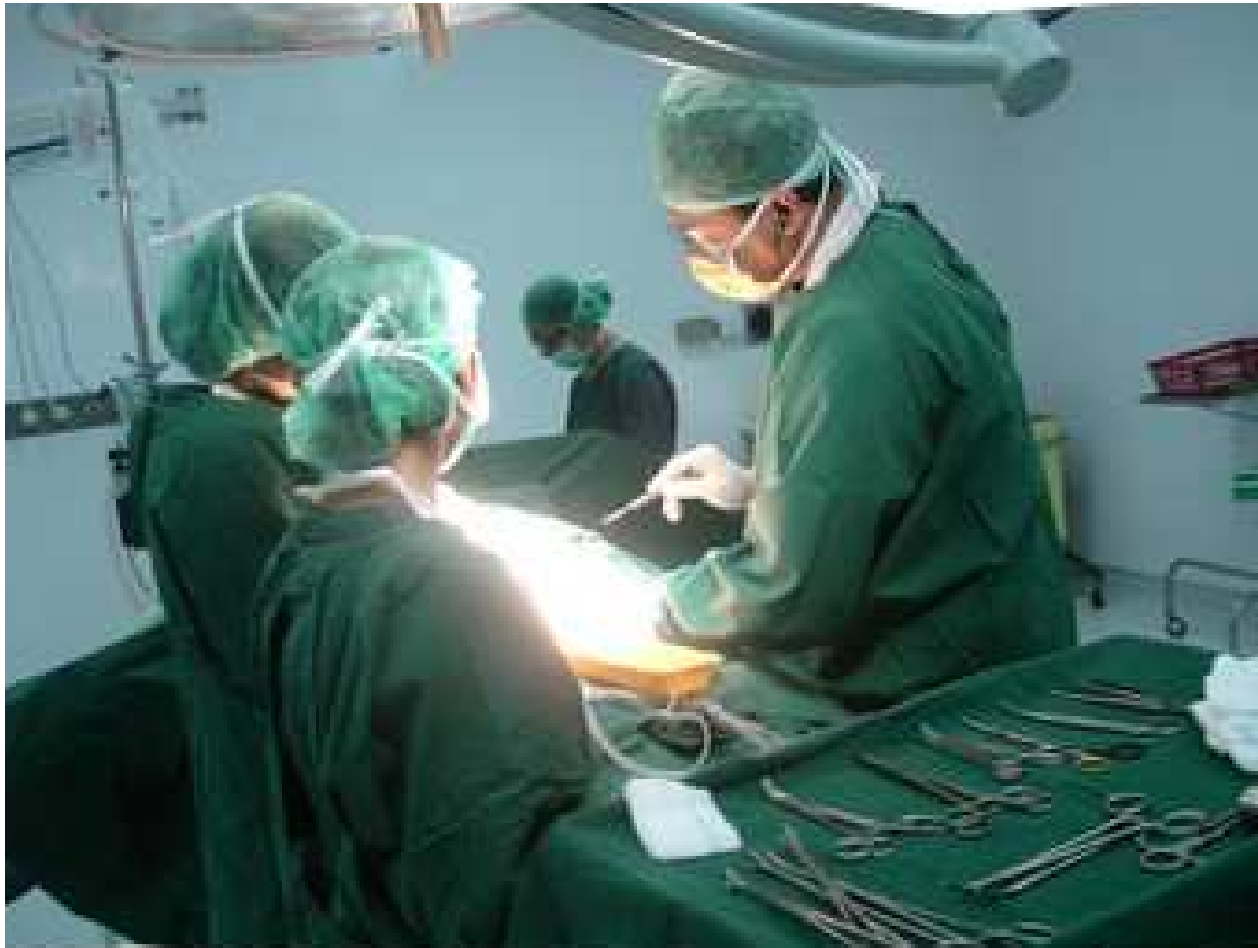Source: Childhood Cancer Registry, Dept. of Child Health, DCH



**[ISU SEPUTAR
KANKER ANAK]**



Kalau dibiopsi bukannya nanti tambah menyebar kankernya?



Tidak ada obat selain kemo dok?

ANALOGI

Di tengah pro dan kontra penggunaan kemoterapi untuk kanker, apa pun pendapat dan alasan orang di luar sana, saya akan tetap merekomendasikannya.

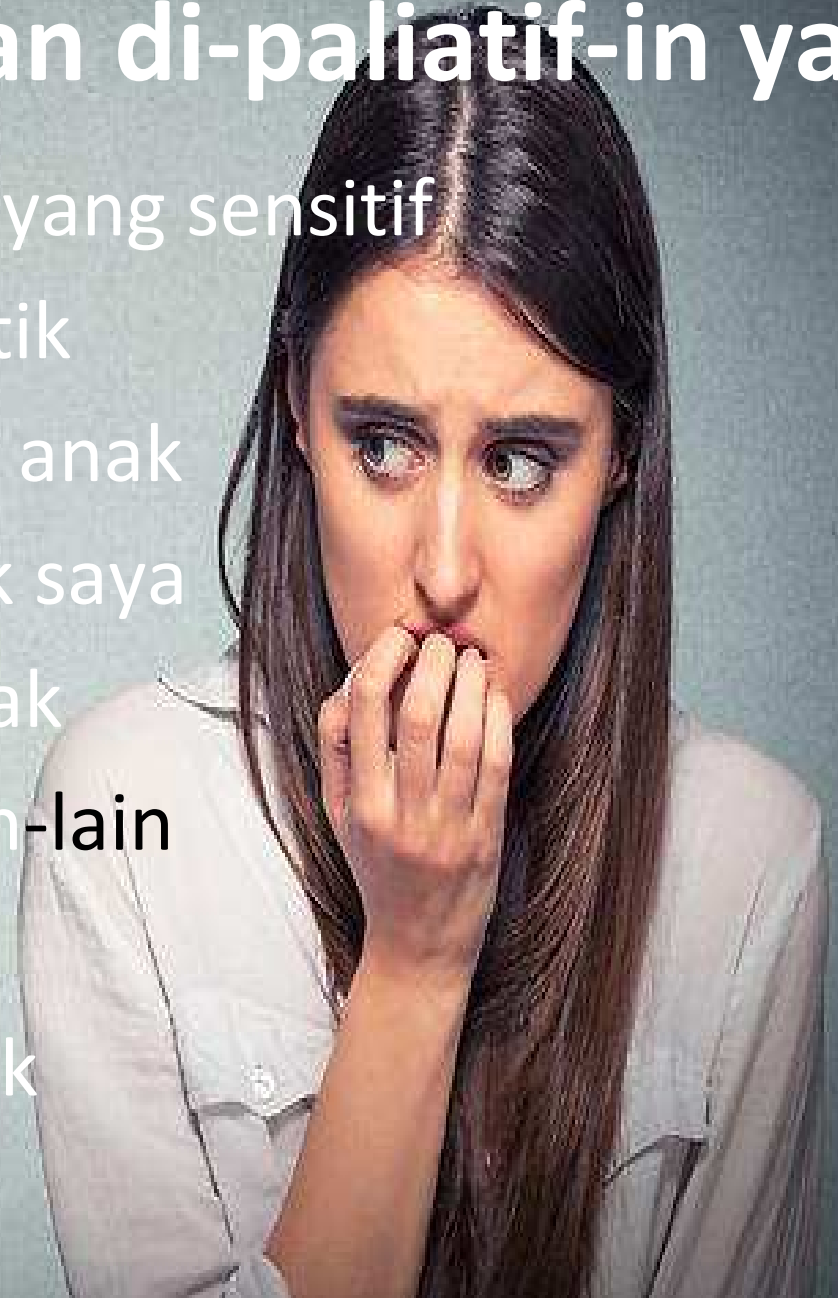Alasannya berhubungan dengan kelebihan obat ini yang tidak dimiliki obat-obat lain yang digunakan untuk tujuan yang sama, yaitu menghancurkan sel kanker. Obat kemoterapi, selain "bodoh", juga sering saya sebut seperti Densus 88 (Detasemen Khusus Antiteror) Polri.

dr. Edi Tehuteru, "Melawan Kanker Bersama 'Si Bodoh'", Koran Tempo, 16 Februari 2016



Anak saya jangan di-paliatif-in ya

- Paliatif menjadi kata yang sensitif
- Paliatif menjadi identik dengan sebentar lagi anak saya meninggal, anak saya tidak diobati lagi, tidak ada harapan, dan lain-lain
- Paliatif artinya saya harus membawa anak saya pulang





Terima
kasih